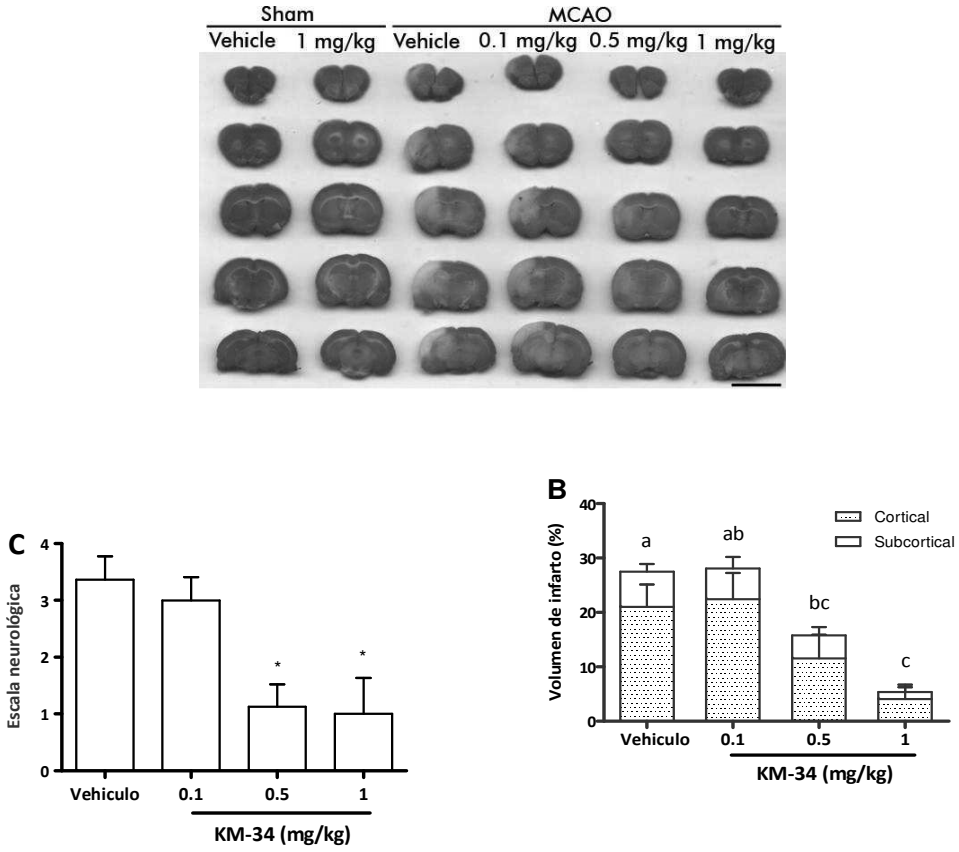

Figure 13. Acute treatment with KM-34 reduced the volume of infarction, edema and deficit in rat behavior after 90 min of middle cerebral artery occlusion (MACA) and 23 hours of reperfusion. The different doses of the compound were administered orally 1 hour after reperfusion. (A) Representative brain coronal sections (2 mm thick) of the sham and ischemic groups treated with vehicle or KM-34 (0.1, 0.5 or 1 mg / kg) and stained with 2,3,5-triphenyltetrazolium (TTC) 2 %. The red regions correspond to undamaged tissue and white to ischemic regions. (B) Quantitative analysis of cortical, subcortical and total lesion size. (C) Neurological deficit. The bars represent the mean ± SEM (n = 8). Different letters in (A) and * in (B): $p < 0.05$, by ANOVA and post hoc of Newman-Keuls. Scale = 10 mm.

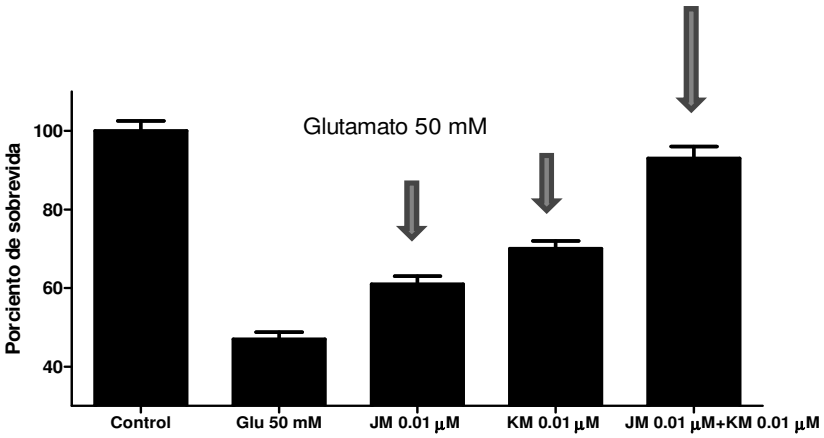
Glutamato 50 mM
Porciento de sobrevida
100
80
60
40
Control
Glu 50 mM
JM 0.01 µM
KM 0.01 µM
JM 0.01 µM+KM 0.01 µM

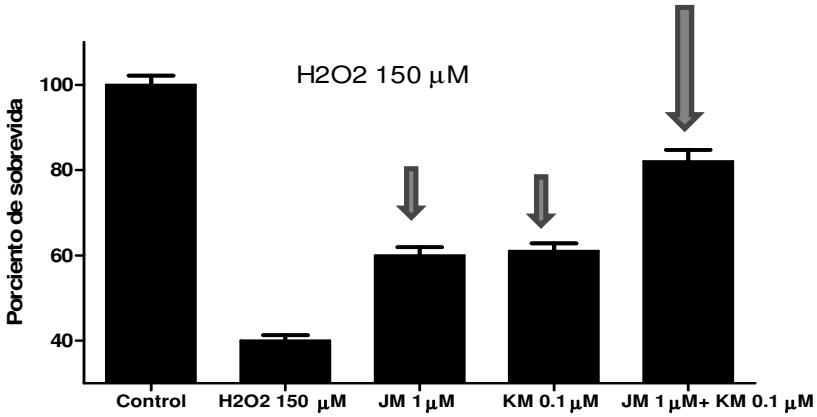
H2O2 150 µM
Porciento de sobrevida
100
80
60
40
Control
H2O2 150 µM
JM 1 µM
KM 0.1 µM
JM 1 µM+ KM 0.1 µM